



September 25th, 2013

RE: Screening for GI Clips in Patients with Recent Colonoscopy or Endoscopy

MEMO TO: Department of Radiology
FROM: Scott Reeder, MD, PhD, Chair of the UW MRI Safety Committee

The purpose of this memo is to provide an update on the status of pre-MRI safety screening in patients who may have had hemostasis clips placed during endoscopy or colonoscopy. The concern is that torquing of a ferromagnetic hemostasis clip in a strong magnetic field could lead to bleeding or injury at the site of biopsy / polypectomy.

1. **Resolution Clip.** Until recently, this clip was considered MR unsafe and UW guidelines required screening for retention of this clip using abdominal radiographs. Recently, the safety rating on this clip was changed to "MRI safe". Therefore, there are no longer any restrictions on scanning patients with the Resolution clip.
2. **Olympus.** There are several models of Olympus GI clips. Two of these models, "Quick-Clip 2" (HX-201LR-135 and HX-201UR-135) are considered MRI unsafe and are contraindications to MRI. UW Gastroenterology uses these clips occasionally (but are phasing them out). It is likely that some outside facilities may use these clips.

According to the package insert for the Olympus clips, it has been shown that Olympus clips are retained for an average of 9.4 days, but possibly longer. According to Shellock et al AJR 2008, 191:1-10, for a patient with a contraindicated Olympus clip, that "before MRI, the physician should confirm that there are no residual clips in the gastrointestinal tract". This can be done via abdominal radiograph or repeat endoscopy / colonoscopy to inspect the same area where the clip was originally placed.

Therefore, screening for patients with possible GI clips continues to be necessary. The length of time needed to screen is unknown, but it is highly unlikely that indefinite screening is necessary since all clips should eventually pass. Since the timing of this passage is unknown, we consider 2 months to be a reasonable time during which a patient with a possible Olympus clip should be screened.

For these reasons, the MRI Safety Screening form, will be modified to ask the following question: "Have you undergone a colonoscopy/endoscopy in the past 2 months?". ***If the patient has not undergone an endoscopy or colonoscopy within the past two months, then the patient is cleared for scanning.***

If the patient answers yes, it should be determined whether a clip was placed, and if so, which type of clip. If the type of clip is known (and is not an Olympus clip) then the patient can proceed to scanning. In the situation where

- 1) it is unknown whether a clip was placed,
- 2) a clip was placed but the type of clip is unknown, or
- 3) an Olympus clip was placed,

then the MRI should be delayed until 2 months after clip placement, if possible. If this delay impacts clinical care, then an abdominal radiograph (preferred) or repeat endoscopy can be obtained to determine whether a hemostasis clip is still present. If no clips are present then the patient can proceed safely to MRI.

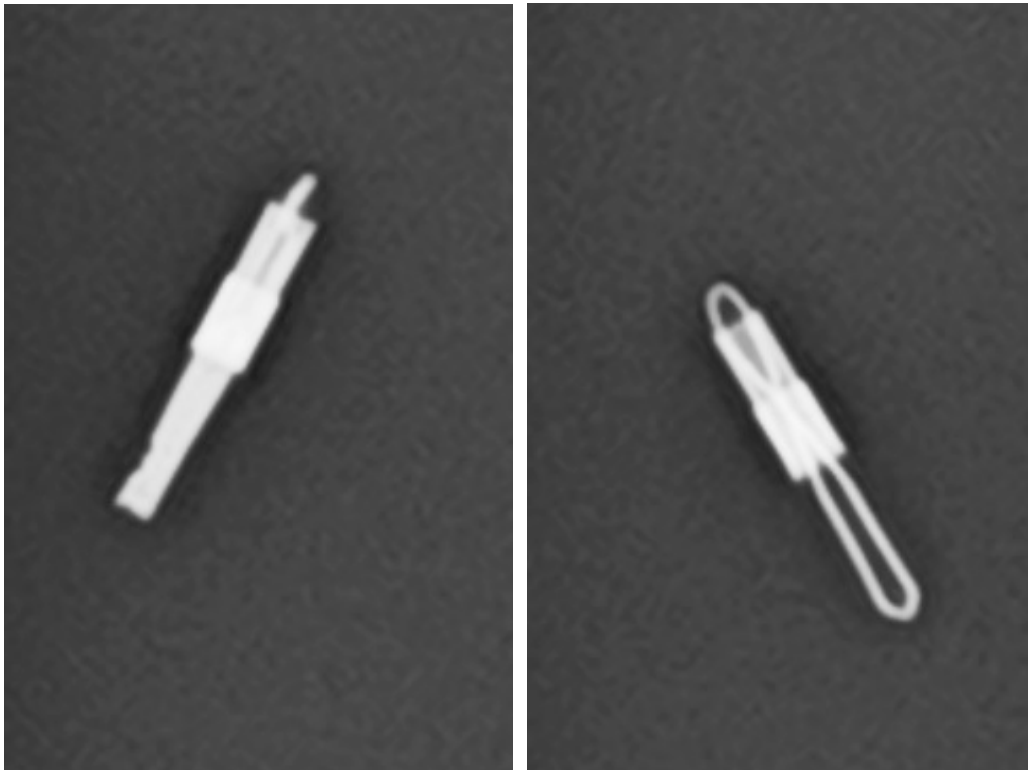
Finally, we recommend that all physicians performing endoscopy / colonoscopy procedures carefully report **1)** whether any hemostasis clips are placed, and if so, **2)** the name of the clip, in order to assist with future MRI safety screening.

Questions can be directed to Scott Reeder, (pager 6713, sreeder@wisc.edu), Liz Sadowski, or Kelly Bybee.



Radiographs of Olympus Quick-Clip 2

The following 2-view radiograph of a deployed Olympus clip is shown to help identify this type of clip.
This clip is *not* MRI safe.





Radiographs of the Resolution Clip

The following abdominal radiograph shows multiple Resolution clips and a zoomed view. This clip *is* MRI safe.

