

Musculoskeletal Imaging and Intervention Section Imaging Procedures

Hip Aspiration or Injection

INDICATIONS

1. Contrast injection for MR Arthrogram: Typically ordered for evaluation of possible labral tear.
2. Anesthetic Hip Arthrogram: In patients with lumbar spine and hip disease to prove if pain is coming from hip.
3. Diagnostic/Therapeutic Arthrogram: This procedure is done to determine if the hip is the cause of a patient's pain and to treat the pain.
4. Rule Out Septic Arthritis:
 - a. Adult
 - b. Child
 - c. Status-post hip arthroplasty

PREREQUISITES

- Obtain signed consent.

TECHNIQUE

1. Place the hip in internal rotation with partial flexion with padding under the knee and a sandbag holding the foot.
2. Mark the lateral margin of the course of the femoral artery using a marking pen.
3. Target a few mm inside the lateral junction of the femoral head and neck and confirm that the femoral vessels are out of the way.
4. Prep and drape with aperture drape and towels.
5. Anesthetize the skin and subcutaneous tissues with buffered 1% lidocaine.
6. The remainder of the procedure depends on the indications:
 - a. **Hip MR Arthrogram and Hip Injections:**
 - i. A 22 G 3½" needle is used for all MR arthrogram injections as well as for anesthetic arthrograms.
 - ii. Place the tip of the needle directly onto the anterior cortex at the spot marked.
 - iii. Confirm intraarticular needle placement with a small injection of Omnipaque 300 and take a spot film (Figure 1).

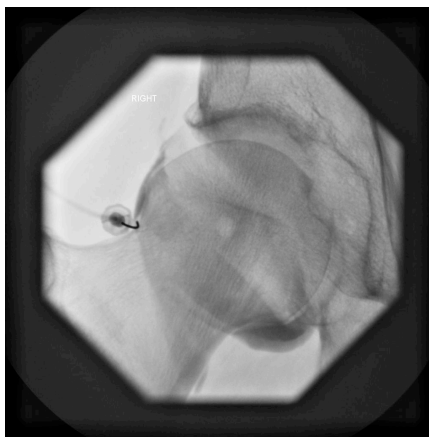


Fig 1: Hip arthrogram, AP.

iv. Inject:

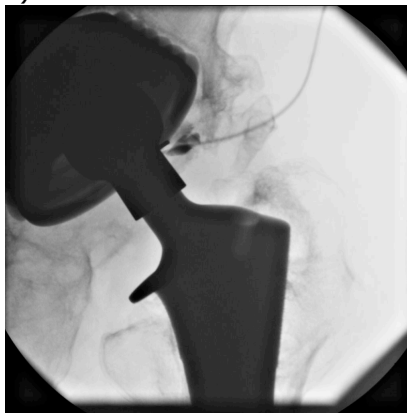
1. **MR Arthrogram** – Inject 10–20 cc of a the standard dilute gadolinium MR arthrogram solution (10 cc normal saline, 5 cc Omnipaque, 5 cc 1% lidocaine, and 0.1 cc gadolinium)
2. **Anesthetic Arthrogram** – Inject 8 cc of a mixture equal parts 2% lidocaine and 0.5% Bupivacaine.
3. **Diagnostic/Therapeutic Injection** – Inject 1 cc of Celestone (6 mg) and 1-2 cc 0.5% Bupivacaine.

b. **Adult Hip and Hip Arthroplasty Aspirations to Rule Out Infection:**

- i. Generally, a 3 ½" 18 G needle is used for all adult arthrograms to rule out infection including hip arthroplasty aspirations. This is because the synovial fluid can be very thick especially if infected.
- ii. Aim for the lateral edge of the prosthesis from a slightly lateral approach. Feel it touch the metal, advance it past the prosthesis, and aspirate as you pull back.
- iii. The joint pseudocapsule can be heavily calcified simulating bone, be sure to feel metal.
- iv. Aspirate the joint with a 20 cc syringe.
- v. If the tap is dry (especially in hip replacements): Inject a small amount of Omnipaque 300 mg under fluoro to insure proper intraarticular needle placement (Figures 2 and 3).

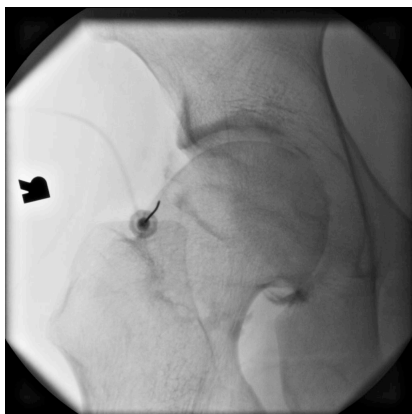

Fig 2: Intracapsular position confirmation,



AP.Fig 3: Hip aspiration with THA, AP.

- vi. Inject 10 cc of sterile normal saline.
- vii. Aspirate the injected saline.
- viii. Inject the fluid into culture tubes, anaerobic and aerobic.

c. **Pediatric Hip Aspirations:**