

Musculoskeletal Imaging and Intervention Section Imaging Procedures

Osteoid Osteoma: CT Guided & Radiofrequency Ablation

RISKS

- Bleeding
- Infection
- Nerve damage
- Vascular damage

PREREQUISITES

- General anesthesia consult
- CT guided biopsy slot under general anesthesia.
- History and physical must be done by referring MD or radiologist.
- Make sure RF probe is available and sterilized.

TECHNIQUE

1. Place patient prone. Optimize access to lesion more than 1 cm away from the neurovascular structures. Position the patient while under general anesthesia.
2. Axial narrowly collimated (3 mm) images with localization grid.
3. Mark the patient; sterile technique.
4. Local anesthetic with lidocaine and Bupivacaine in tract to decrease post-procedure pain.
5. Aspirate joint effusion (if intraarticular) and make dermatotomy.
6. Advance 11G Jamshidi to bone surface, embed trochar tip, image position.
7. Twist the outer cannula of the Jamshidi just into the cortex; remove trochar.
8. Place 15G ostycut outer cannula coaxially through the Jamshidi outer cannula and twist into the lesion. Need 15 cm ostycut for 10 cm Jamshidi.
9. Image position and remove core samples. Send to pathology in formalin (Figure1)

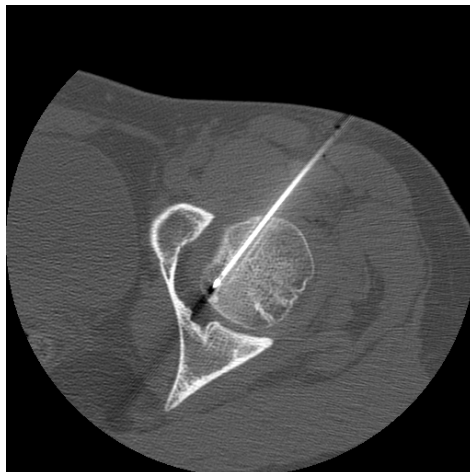


Fig 1: Biopsy needle positioning confirmed on CT.

10. Hook up RF probe to wire and place the RF probe tip into the lesion and defect created by osty cut biopsy. The active end of the probe (1 cm) must NOT be in contact with the Jamshidi or the tract along the Jamshidi will fry. Poor form.
11. Image the position of the probe tip.
12. Test the RF probe for nearby nerve stimulation (muscle contractions).
13. RF lesion generator – 4-6 min at 85°-90°C.
14. Remove the probe.
15. Inject Bupivacaine into the joint (if intraarticular)
16. Remove the Jamshidi, hold pressure, and dress.

POST-OP CARE

- Tylenol #3, 1 tab PO q 4-6 hr x 2 weeks.
- Crutches with toe touch weight bearing x 2 weeks (if lower extremity lesion).
- Follow up in Ortho Clinic, 2 weeks.
- Watch for infection.