



**Department of Radiology**  
UNIVERSITY OF WISCONSIN  
SCHOOL OF MEDICINE AND PUBLIC HEALTH

**Musculoskeletal Imaging and Intervention Section Procedures**  
Intra-articular Cervical Facet Joint Corticosteroid Injection

**INDICATIONS**

- Clinical diagnosis/'facet syndrome' – localized tenderness, pain with hyper-extension
- Diagnostic injection

**RISKS**

- Bleeding
- Infection
- Pain
- Transient Paralysis

**MODALITY**

- Fluoroscopy

**PRE-PROCEDURAL WORKUP**

- AP & lateral views of the spine (cross-sectional imaging preferred)
- Informed consent

**MATERIALS**

- Alcohol, betadine, sterile drape
- 10 mL syringes for skin anesthetic and steroid/anesthetic mixture
- 5 mL syringe for Omnipaque 300 (5 mL)
- 1% lidocaine (for skin numbing); buffered with 8.4% sodium bicarbonate
- Dexamethasone sodium phosphate (10 mg/mL)
- Ropivacaine HCL 0.5% (Naropin 5 mg/mL)
- 30G 0.5", 25G 3.5", or 22G 1.5" & 3.5" needles

**Department of Radiology**

Musculoskeletal Imaging and Intervention

## TECHNIQUE

1. Posterior approach:
  - a. Position the patient prone with proper support. The patient's head should be flexed and turned ipsilateral to the side being injected. The important structures to avoid include the spinal cord which is situated medial to the facet joints, as well as the neurovascular structures ventrally.
  - b. The advantage to this approach is that multiple levels on either side of the spine can be injected without repositioning. An AP view with caudal tilt is the trajectory view, also called the pillar view (Fig. 1). Depth is assessed with a lateral view.
    - i. If the joint is not well visualized on the lateral view, an approximate 30-degree CLO (contralateral oblique view) can be utilized, which allows assessment of the ipsilateral neural foramen (Fig. 3-4 & 11-12).
  - c. Confirm your level of injection with the trajectory view. The tube may be tilted caudally to be in line with the facet joint. Proper positioning is obtained when the joint space is clearly marginated. Mark the skin at the inferolateral aspect of the joint. Advance the needle tip into the lateral joint space and confirm intra-articular placement with a drop of Omnipaque 300.
    - i. A linear band of contrast on the AP view denotes appropriate intra-articular positioning (Fig. 2). Contrast will outline the joint on the lateral view.
    - ii. A common phenomenon is retro-ligamentous flow within the space of Okada, which is an epidural space dorsal to the ligamentum flavum. Contrast will be seen flowing medially from the inferior joint recess.
2. Lateral approach:
  - a. Position the patient in the lateral decubitus position with the side to be injected facing upward. Confirm your level of injection with a lateral view (Fig. 5 & 9). This is your trajectory view. Obtain your pillar view after your skin marking for needle entry is performed (Fig. 13).
  - b. Rather than a CLO view, an *ipsilateral* oblique view is used in this approach to assess the neural foramen. This view is also used to confirm needle placement. The lateral masses do not appear superimposed in this view.
  - c. Appropriate flow of contrast to confirm intra-articular placement appears as a linear band, which may extend to both the superior and inferior joint recesses (Fig. 6-8, 10 & 14).
3. The corticosteroid mixture for injecting two joints consists of 1 mL 1% preservative-free lidocaine and 1 mL dexamethasone. 1 mL should be injected in each joint.

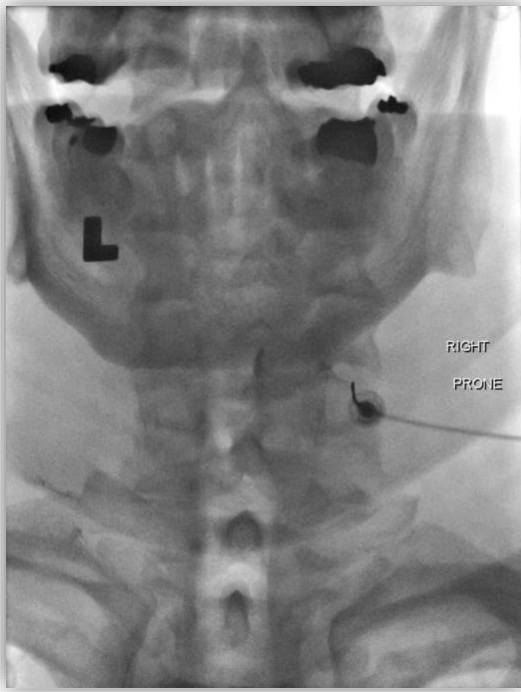


Fig 1. Trajectory view with the needle in position within the right C5-6 facet joint.

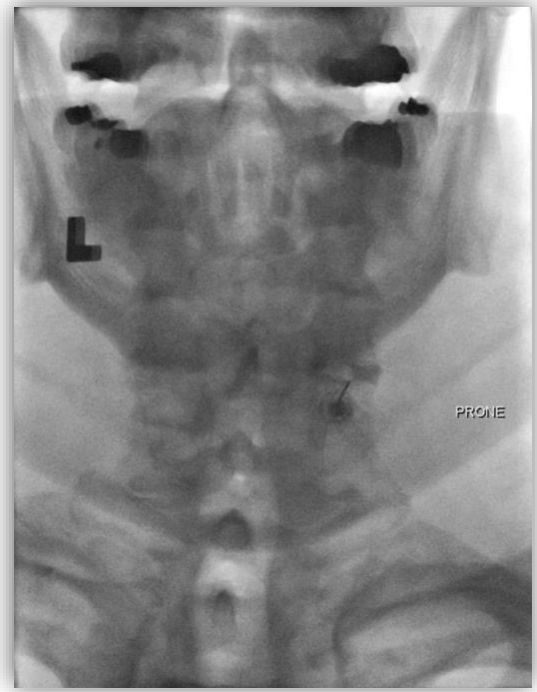


Fig 2. Subsequent trajectory view of Figure 1 demonstrating presence of intra-articular within the right C5-6 facet joint.

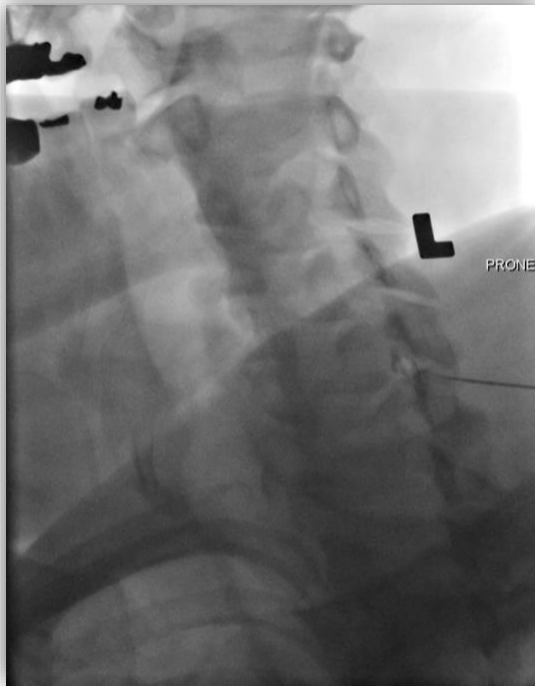


Fig 3. CLO view with the needle tip in ideal position within the right C5-6 facet joint of the same patient in Figures 1 & 2. A small amount of intra-articular contrast is visualized within the superior recess.

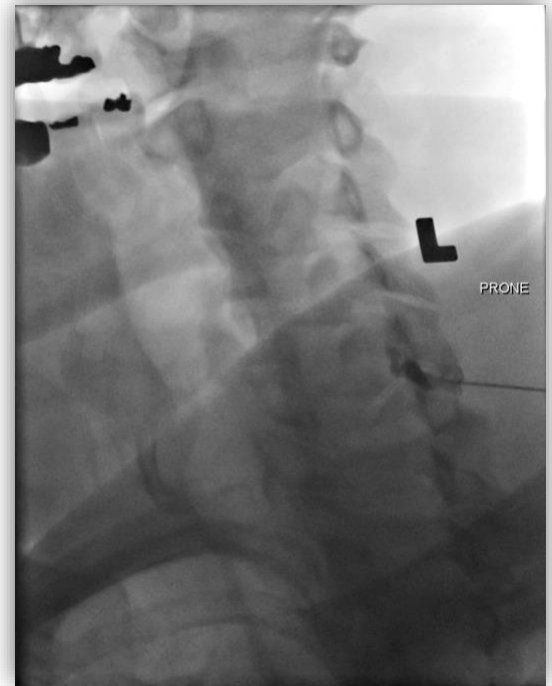


Fig 4. Subsequent view of Figure 3 demonstrating further opacification of the right C5-6 facet joint.

**Department of Radiology**

Musculoskeletal Imaging and Intervention

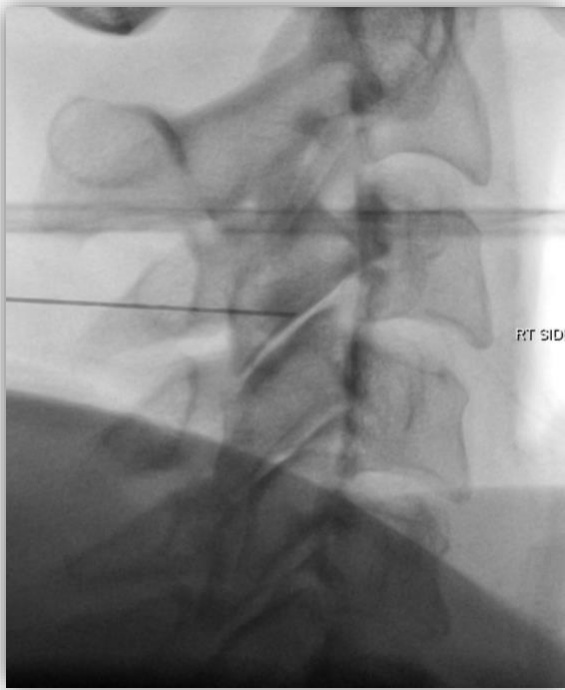


Fig 5. Lateral view demonstrating ideal skin marking site for a right C3-4 facet joint injection.

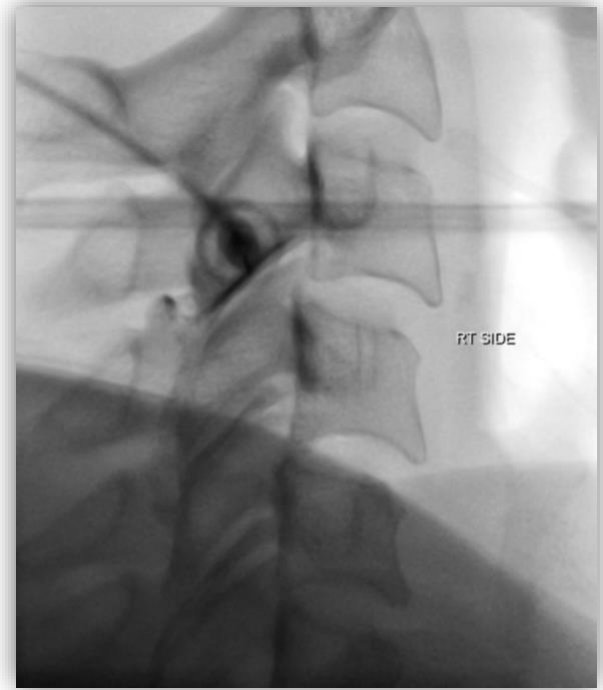


Fig 6. Subsequent view of Figure 5 demonstrating contrast flow within the right C3-4 facet joint space.

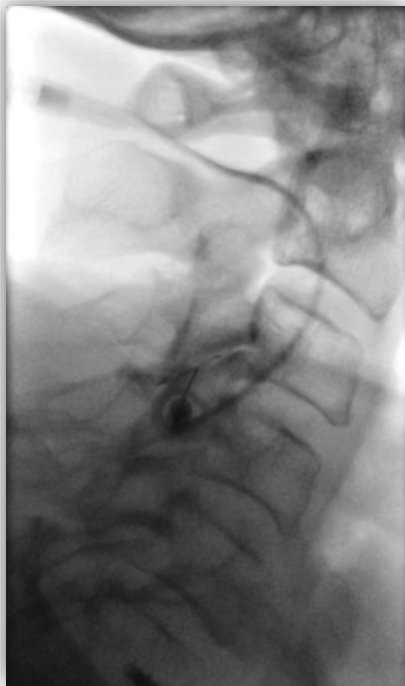

Fig 7. Lateral view of a different patient demonstrating optimal contrast flow within the C3-4 facet joint space.

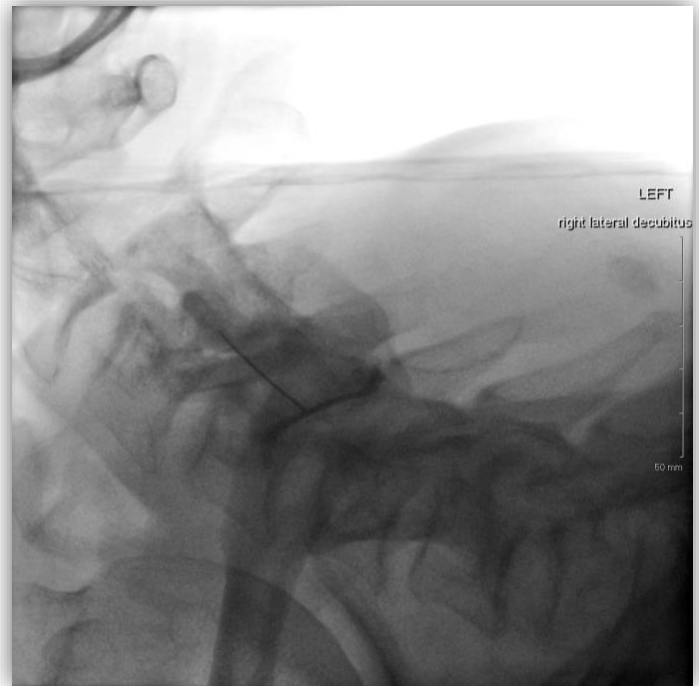

Fig 8. Lateral view of another patient of a left C4-5 facet joint injection with intra-articular contrast visible within the joint space.

### Department of Radiology

Musculoskeletal Imaging and Intervention

University of Wisconsin School of Medicine and Public Health Clinical Science Center 600 Highland Ave Madison, Wisconsin 53792-3252  
608/263-9387 Fax: 608/263-5112 <https://radiology.wisc.edu/sections/musculoskeletal-imaging-and-intervention/>

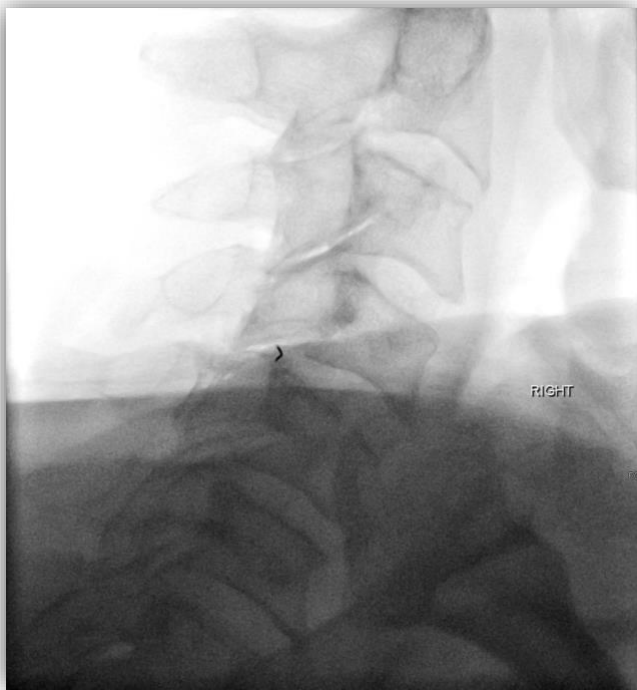

Fig 9. Lateral view demonstrating optimal needle tip positioning within the right C4-5 facet joint.

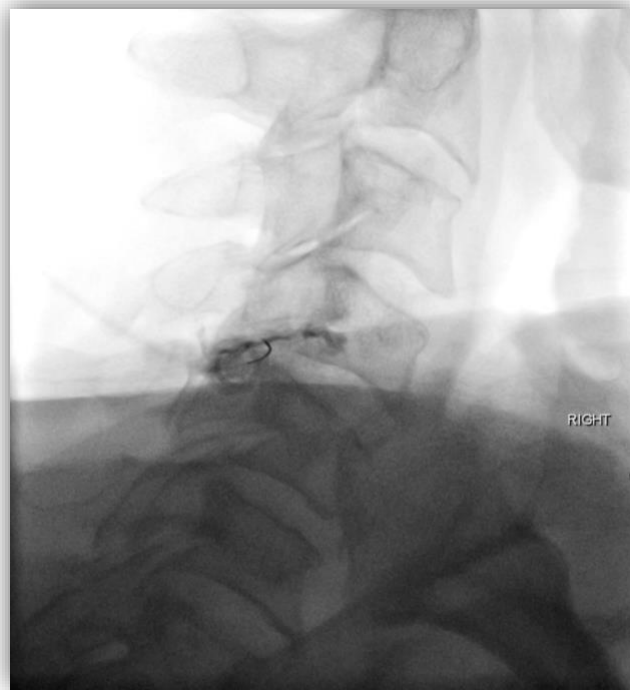

Fig 10. Subsequent view of Figure 9 showing injection of the right C4-5 facet joint with optimal contrast flow between the anterosuperior and posteroinferior joint margins.

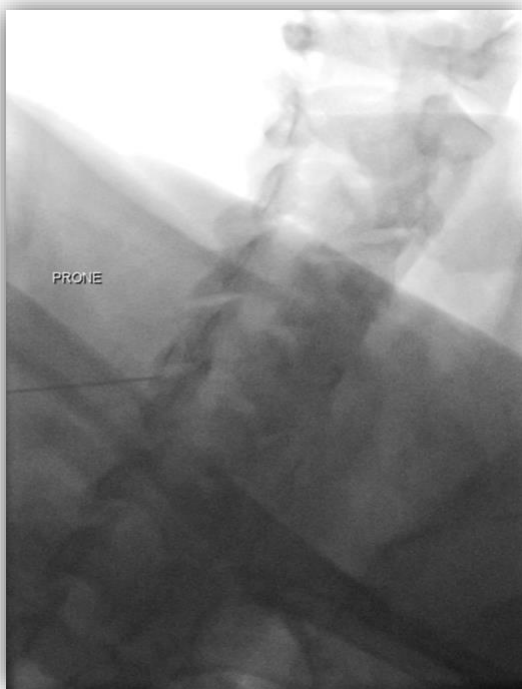


Fig 11. Contralateral oblique view with ideal needle tip positioning within the left C5-6 facet joint.

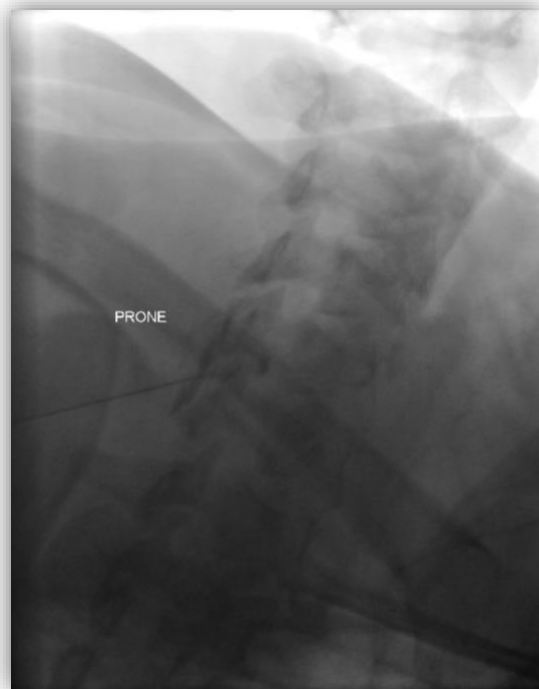

Fig 12. Subsequent view of Figure 11 demonstrating presence of intraarticular contrast within the left C5-6 facet joint.

### Department of Radiology

Musculoskeletal Imaging and Intervention

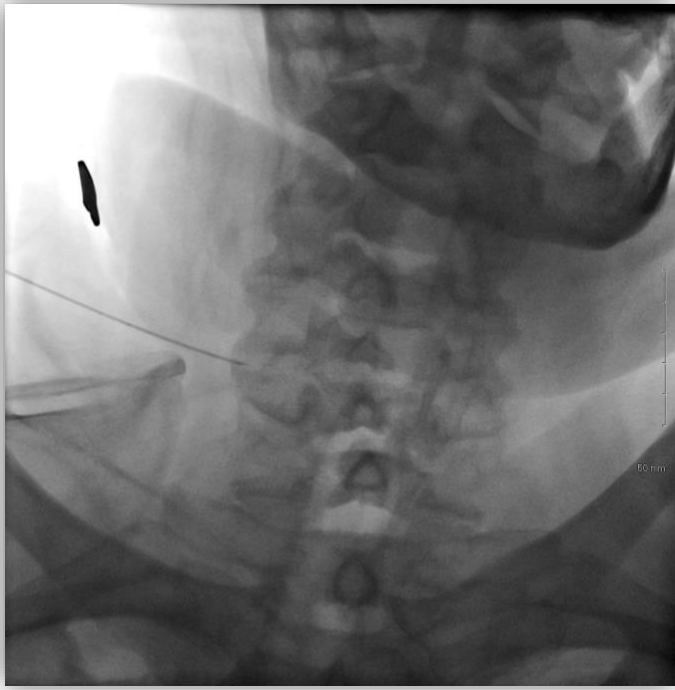


Fig 13. AP view with ideal needle tip positioning in the right C5-6 facet joint.

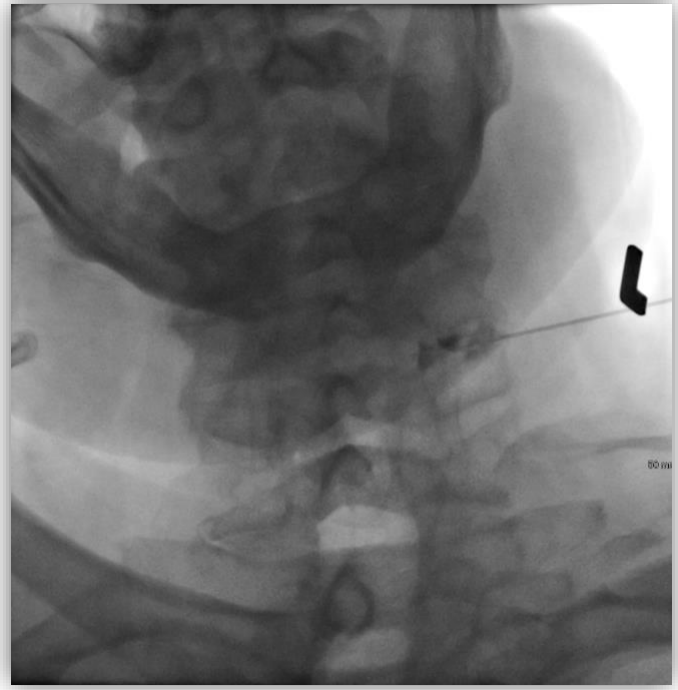

Fig 14. AP view of the same patient, now demonstrating a left C5-6 facet injection with optimal contrast flow.

Prepared by: Mitchell Fox, MD – 06/2022

**Department of Radiology**

Musculoskeletal Imaging and Intervention

University of Wisconsin School of Medicine and Public Health Clinical Science Center 600 Highland Ave Madison, Wisconsin 53792-3252  
608/263-9387 Fax: 608/263-5112 <https://radiology.wisc.edu/sections/musculoskeletal-imaging-and-intervention/>

