

Division of Nuclear Medicine Procedure / Protocol University Hospital and The American Center

HEPATOBIILIARY IMAGING without pharmaceutical intervention (none or Ensure Plus)

CPT CODE: 78226

HEPATOBIILIARY IMAGING with pharmaceutical intervention (sincalide or morphine after mebrofenin)

CPT CODE: 78227

UPDATED: February 2021

Indications (All):

- Diagnosis of acute cholecystitis (both calculus and acalculous disease)
- Determination of patency of common bile duct when ultrasound examination not diagnostic (e.g., very early obstruction)
- Evaluation of biliary dyskinesia (gallbladder ejection fraction [GBEF] test) for chronic cholecystitis
- Identification of biliary leaks
- Differentiation of biliary atresia from neonatal hepatitis
- Evaluation of presence, or absence of, spleen (with T-99m SC Liver Scan).
- Suspected sphincter of Oddi dysfunction or partial biliary obstruction due to stones or stricture.

Acute Cholecystitis

Patient Preps:

See Acute Cholecystitis algorithm below, Appendix 2

No Pre-Treatment:

- Fasting for a minimum of 2 hours, but preferably 4 hours before this test.
- Parental alimentation (ex. TPN) is allowable and considered to be a fasting state.

Pre-Treatment:

- Record any recent hydromorphone (Dilaudid), fentanyl, or morphine used in last 12 hours; refer to morphine use section below and opioid table in Appendix 1.
- In patients who have fasted for greater than 24 hours, on parenteral nutrition, or with a history of alcoholic liver disease, Sincalide (Kinevac) should be administered prior to tracer injection. Sincalide administration of 0.02 microgram/kg is to be over 30 min. Mebrofenin injection can be started 15-60 min after Sincalide infusion is completed. On-call cases of fasting state for pre-treatment sincalide administration should be determined by the technologist with the patient's nurse (***If there is any question or lack of information of a fasting state, sincalide pre-treatment should be administered prior to imaging to clear the gallbladder.***)
- In case of sincalide shortage, consider ensure PO pre-treatment prior to fasting as tolerated and allowed by the referring clinician

Prep Modifications:

If Total bilirubin >10 (within the last week)

Consult with the Nuclear Medicine Physician, a 1.5 to 2-fold increase in dosage may be prescribed and a longer imaging time requested.

Critically ill patients with sepsis

Require an IV Sincalide administration of 0.02 microgram/kg is to be over 30 min prior to scan and possibly larger doses of morphine (0.08 mg/kg) (especially when acute acalculous cholecystitis) (requires faculty approval) with more delayed images (30-40 min post morphine). If the patient is on gastric tube feedings, Sincalide is unnecessary. If tube feeding is into the proximal small bowel then Sincalide pre-treatment is required.

Scheduling:

- Allow 150 min of camera time. Delayed images are at 2 hours and 3-4 hours post-injection 99mTc - Mebrofenin. Imaging 24 hours post-injection is possible.
- If pre-treatment is required account for the additional 30-minute infusion time. Then schedule as above for acute cholecystitis.

Division of Nuclear Medicine Procedure / Protocol University Hospital and The American Center

Radiopharmaceutical & Dose:

99mTc-Mebrofenin 5 mCi +/- 20% (4-6 mCi) IV, adjusted for weight per NMIS.

If patient is jaundiced (bilirubin > 10): NM physician should be consulted prior to dosing 99mTc-Mebrofenin to determine possible increase in dose (1.5-2 times) and/or adjustment of imaging times.

Sincalide 0.02 microgram/kg IV diluted with NaCl to 50 ml and infused over 30 minutes as a pre-treatment and over 60 minutes when for GBEF.

Sincalide (Kinevac) Preparation (Gallbladder EF):

- **Reconstitution:** Add 5 ml of sterile water to Kinevac vial containing 5 micrograms to create a solution of 1 microgram/ml.
- **Dose Preparation:** Obtain patient's weight in kg and calculate dose at 0.02 microgram/kg. Withdraw dosage from vial and add to a 60 ml syringe loaded with 0.9% NaCl. Total volume with Kinevac and NaCl to be 50 ml. Dose is stable for 1-hour post-dilution of saline.
- **Infusion Pump:** Attach extension tubing to 60 ml syringe of Kinevac and place in infusion pump. Set up pump as single dose, B-D syringe, 50 ml dose for 60 min.

Morphine Use in Hepatobiliary Scans:

- Morphine 0.04 milligram/kg IV when indicated per protocol.
- Confirm patient is not allergic to morphine.
- Record any hydromorphone (Demerol), fentanyl, or morphine used in last 12 hours. If the patient is on opioids (within 5 half-lives - refer to **OPIOID REFERENCE TABLE** below (Appendix 1), get approval from referring clinician regarding approval to administer morphine for hepatobiliary scan.
- If the patient is an outpatient confirm they have a designated driver.
- The use of intravenous Morphine (0.04mg/kg to a max of 4 mg) is used as part of the functional assessment of the gallbladder in the hepatobiliary scan protocol. The hepatobiliary scan protocol includes the use of IV Morphine to elevate the pressure in the extrahepatic bile duct system and so fill the gallbladder. This has been established to improve the sensitivity and specificity of diagnosing acute cholecystitis.
- The section of nuclear medicine has used this Morphine-augmented protocol for 15 years without a single incident, and never had to inject a reversal agent.
- This sectional protocol establishes that the Hospital-wide conscious sedation does not apply to this diagnostic test (just as it does not apply to pain relief use of narcotics). The protocol does require a physician be available to supervise the administration of the Morphine, but this physician does not need to be credentialed for conscious sedation.

PROCEDURE WHEN USING MORPHINE FOR PATIENT EXAMS:

- Fill out the sign-out form that is kept in the safe with the morphine.
- Do **NOT** fill out the pharmacy charge form.
- Morphine is supplied 5 mg/ml at 1.0 ml. Morphine that is **NOT** used for the exam must be disposed of and accounted for. This must be witnessed by another person, disposed of, and initialed by both parties.
- Update balance sheet with patient name and data.
- Return paperwork to safe, and lock.

NOTE: If the dose of Morphine is more than 4.0 milligram, **CONSULT WITH STAFF BEFORE INFUSION.**

Division of Nuclear Medicine Procedure / Protocol University Hospital and The American Center

Imaging Device:

GE Infinia, Optima or Millennium MPS gamma camera with LEHR collimator.

Imaging Procedure:

See Acute Cholecystitis algorithm below, Appendix 2

- 1) Technologist will verify the patient prep of NPO status and when/what they last ate. Also verify what opiates they are on and when the last dose was given. The Faculty or Resident will as well verify NPO and opiate status including whether or not morphine be administered if needed on top of current opioids.
 - a) NM Faculty or Resident will determine if pre-treatment with sincalide is needed and place the IP order. Typically, pre-treatment is needed when there has been no PO intake in the past 24 hours or greater.
 - b) If pre-treatment is given imaging cannot start earlier than 15-60 minutes post the completion of the 30-minute sincalide infusion.
- 2) Position patient supine under the camera.
- 3) Image immediately after injection
- 4) Dynamic Acquisition in the anterior projection unless otherwise indicated:
 - a) 1st Set: On the acquisition computer image set up, set image identifiers to: **Ant 0-45 1m/f**. Where “ant” is replaced with the actual projection if another is used. 1 min/frame x 45 min, 128 x 128, 1.0 zoom, 20% window peaked for 99mTc. Start acquisition after injection.
 - b) 2nd Set: On the acquisition computer image set up, set image with identifier: **Ant 45-120 1m/f**. Where “ant” is replaced with the actual projection if another is used and adjust “120” as needed afterwards based on actual study timing. 1 min/frame x 75 min, 128 x 128, 1.0 zoom, 20% window peaked for 99mTc. Start at the 2nd set at the end of 1st set. This set can be stopped 30-60 minutes post morphine or when gall bladder is visualized (evaluate with NM faculty/resident); ending on a frame that is a multiple of 5. (This will help later with post processing.)
- 5) **Evaluate with NM faculty/resident the 0-45-minute images** (while the second set is being acquired):
 - a) Is there sufficient hepatocyte function? (Blood pool clearance from the heart). If no, consider 24 hour delayed imaging.
 - b) Is the common bile duct and duodenum visualized, but the gallbladder does not, consider morphine or delayed imaging.
 - i) If morphine is indicated:
 - (1) Obtain patient weight in kg and calculate dose at 0.04 milligram/kg. Use larger doses of morphine in acute acalculous cholecystitis (requires faculty approval).
 - (2) The NM Faculty or Resident or Nuclear Medicine technologist is to slowly administer the morphine over a 2-minute period at 60 minutes post radiopharmaceutical injection. Consider an additional half dose 99mTc-Mebrofennin, based on the original dose, before the morphine administration. During the business day confirm the additional half dose of 99mTc-Mebrofennin when confirming morphine. When performed on-call the additional 99mTc-Mebrofennin will be given when morphine is given.
 - (a) The duodenum should demonstrate decreased and changing activity to confirm the sphincter of Oddi has contracted.
 - (b) Gastric reflux often occurs in about 60% of patients with morphine.
 - (c) The sedation policy does not apply to this diagnostic use of IV morphine. See disclaimer above.
 - (3) Continue imaging to 30-60 minutes post morphine or until the gallbladder is visualized (evaluate with NM faculty/resident).
 - ii) If delayed imaging is indicated: Image at 2 hours and 3 to 4 hours post injection.

Division of Nuclear Medicine Procedure / Protocol University Hospital and The American Center

Continues on the next page

- 6) Once the gallbladder is believed to be visualized confirm with a Right lateral (or steep RAO if the lateral is not obtainable) and LAO static views for 5 minutes in a 128x128 matrix. Image identifiers include the time post 99mTc-Mebrofenin injection, i.e. **Rt Lat 45 min**. The technologist can take these views as a part of the evaluation in point 5 above if they feel the gallbladder is filling.
 - a) If these views confirm gallbladder, imaging is complete.
 - b) If these views do not confirm the gallbladder
 - i) Set up and start another 1 min/frame x 90 min, 128 x 128, 1.0 zoom, 20% window peaked for 99mTc. Set the image identifiers: **Ant xx-yy 1m/f**. Adjust “xx and yy” as needed afterwards based on actual study timing.
 - ii) Return to point 5 above if morphine or delayed imaging has not been done. If both have been done, at the discretion of the NM Faculty/Resident the exam is likely complete with an Acute Cholecystitis result.

Comments:

A Nuclear Medicine staff or resident physician should be consulted to determine if additional views are indicated.

Data Analysis:

- 1) Combine all sequentially acquired 1 min/frame dynamic images into one dynamic; label it **Ant 0-xx 1m/f**, where XX is the total acquisition. (No screen cap of this image set)
- 2) Reframed the combined dynamic and any other dynamic into 5 minute/frame image sets then Save As in a new series for each reframed set. Each new series and image set will have the identifier **Ant 0 - xx 5m/f** or **Ant yy-zz 5m/f** as appropriate.
- 3) Screen cap the reframed 5 minute/frame image sets on a 4 x 3 display.
 - a) Under first image: **ANT 5min/frame →**,
 - b) Over the first image: time post 99mTc Mebrofenin, for example **0 min post 99mTc Mebrofenin** on the first screen cap and **60 min post 99mTc Mebrofenin** on the second screen cap etc.
 - c) Add under the respective image, based on time image, the 2nd 99mTc-Mebrofenin dose (dose & time) and/or morphine injection (dose & time) if given, where time is in regard to the initial 99mTc-Mebrofenin dose.
 - d) Add Rt/Lt orientation to first image
 - e) Screen Cap label - add to the front of the screen cap label: **ANT 0-xx min** or **Ant yy-zz min**.
- 4) Screen cap static images on a 4 x 3 display and annotate
 - a) View/projection with time reference post 99mTc-Mebrofenin injection, i.e. **Ant 2-hour delay**
 - b) Add Rt/Lt or Ant/Post etc. orientation to each image.
 - c) Screen Cap label - add to the front of the screen cap default label: **Static Delays**.

PACS:

- Send all 1-minute dynamic datasets: **As labeled above**
- Send all 5-minute reframed dynamic datasets: **As labeled above**
- Send all static images: **As labeled above**
- Send all Screen Caps: **As labeled above**
- Using paper scanner, scan in **ONLY** the worksheet.

Division of Nuclear Medicine Procedure / Protocol University Hospital and The American Center

Sphincter of Oddi Dysfunction (SOD) with Sincalide:

Patient Preps:

- Fasting for minimum of 2 hours. Patients should not have had any opiate drug (hydromorphone, fentanyl or morphine) within 6 hours; refer to opioid table in Appendix 1 for adjustments to the 6 hours.
- Patients then should be pretreated with Sincalide (Kinevac) at a rate of 0.02 microgram/kg over 30 minutes.
- Mebrofenin injection can be started 15-60 min post Sincalide infusion.

Scheduling:

Pre-Treatment: Infusion of Sincalide over 30 minutes.

Injection: 15-60 minutes after completion of Sincalide begin imaging for 60 min. Allow 90 minutes of camera time. Delayed images are not typically needed.

Radiopharmaceutical & Dose:

See Acute Cholecystitis

Imaging Device:

GE Infinia, Optima or Millennium MPS gamma camera with LEHR collimator.

Imaging Procedure:

- 1) Place an IV (per hospital policy).
- 2) Infuse the patient with sincalide over 30 minutes as described above.
- 3) Anterior projection imaging should be started 10-60 minutes after the completion of the sincalide infusion.
- 4) Imaging parameters: Dynamic acquisition 1 min/frame x 60 frames, 128 x 128, 1.0 zoom, 20% window peaked for 99mTc. Set image identifier to: **Ant 0-60 1m/f**.
- 5) Process the images per data analysis below.
- 6) Check images and data generation with the reading room prior to releasing the patient.

Comments:

A Nuclear Medicine staff or resident physician should be consulted to determine if additional views are indicated.

Data Analysis:

Prior to analysis check raw images to determine if the Motion Correction program needs to be performed.

- 1) Create a composite image of the 1 min/frame dynamic image set into one 60 min image. Image identifier: **Ant 0-60 1m/f**
- 2) Use the predefined ROI Comparative Analysis protocol
- 3) Draw a region of interest around the right lobe of the liver and one around the common bile duct. Make sure these ROIs do not overlap each other, the small bowel or other liver anatomy. (Check with physician if hard to define proper ROI.)
- 4) Draw a background ROI
- 5) Create a background corrected time activity curve: take the right lobe ROI and subtract the background ROI.
- 6) Create a background corrected time activity curve: take the common bile duct ROI and subtract the background ROI.
- 7) Properly annotate each ROI and SCREENCAP

Continues on the next page

Division of Nuclear Medicine Procedure / Protocol University Hospital and The American Center

- 8) Reframe the 1 min/frame dynamic image set into a 5 minute/frame image set; image identifier Ant 0-60 5m/f.
 - a) Screen cap in a 4 x 3 display and Annotate -
 - i) Over first image: sincalide dosage. For example, x.xx mcg sincalide given X minutes pre-99mTc Mebrofenin.
 - ii) Under first image: **ANT 5 min/frame**→
 - iii) Add Rt/Lt orientation to first image.
 - b) Screen Cap label - add to the front of the screen cap default label: **ANT 0-60 5m/f.**

PACS:

- Send all 1-minute dynamic datasets: **As labeled above**
- Send all reframed 5-minute dynamic datasets: **As labeled above**
- Send all Screen Caps: **As labeled above**
- Send the data generated images (time-activity curves): **As labeled above**
- Using paper scanner, scan in **ONLY** the worksheet.

Gall Bladder Ejection Fraction

Patient Preps:

- Fasting for a minimum of 2 hours, but preferably 4 hours before this test.
- Patients should not have had any opiate drug (hydromorphone, fentanyl or morphine) within 6 hours; refer to opioid table in Appendix 1 for adjustments to the 6 hours.

Scheduling:

- Injection: allow 15 min.
- Scan: Image 45 min post injection, allow 90 min camera time.

Radiopharmaceutical & Dose:

See Acute Cholecystitis

Imaging Device:

GE Infinia, Optima or Millennium MPS gamma camera with LEHR collimator.

Imaging Procedure:

GBEF (Gallbladder Ejection Fraction) with Sincalide

- 1) Place an IV (per hospital policy).
- 2) Check availability of camera with imaging technologist.
- 3) Inject the patient with 99mTc Mebrofenin via IV push.
- 4) Pre-EF (for positioning) with IV sincalide
 - a) The pre-EF imaging should be started 45-55 minutes post injection of 99mTc Mebrofenin.
 - b) Imaging Parameters: Dynamic acquisition 1 min/frame x 5 frames, 128 x 128, 1.0 zoom, 20% window peaked for 99mTc, with image identifier of **Pre-EF**. (Projection/View not needed as it may be adjusted during this acquisition.) This dynamic image will not be sent to PACS.
 - c) **CHECK POSITIONING WITH NUC MED PHYSICIAN DURING THE previously described DYNAMIC ACQUISITION AND BEFORE ADMINISTERING SINCALIDE.** Stop above acquisition when positioning is approved.

Continues on the next page

Division of Nuclear Medicine Procedure / Protocol University Hospital and The American Center

- 5) Sincalide Infusion Imaging Parameters
 - a) **ADMINISTER SINCALIDE IF:**
 - Most of the activity is in the gallbladder and bowel with relatively little in the liver.
 - Ensure the gallbladder is separated from the duodenum by utilizing the LAO view, if necessary.
 - NM Faculty or Resident could ask for a delay in starting the sincalide infusion. Another pre-infusion imaging set will be required. Exam could also be canceled if the gallbladder does not fill sufficiently.
 - b) Imaging Parameters: Dynamic acquisition 1 min/frame x 60 frames, 128 x 128, 1.0 zoom, 20% window peaked for 99mTc, with image identifier of **ANT or LAO EF 1m/f**. Sincalide administration and camera acquisition are started at the same time; this should be 50-60 minutes post 99mTc Mebrofenin injection.
 - c) Sincalide is infused over 60 minutes; camera is set up to automatically save and transfer images when compete. There is no stopping the acquisition early.

Comments:

A Nuclear Medicine staff or resident physician should be consulted to determine if additional views are indicated.

GBEF (Gallbladder Ejection Fraction) with 8 fl. oz. (240 mL) of Ensure Plus®

- 1) Place an IV (per hospital policy).
- 2) Check availability of camera with imaging technologist.
- 3) Inject the patient with 99mTc Mebrofenin via IV push.
- 4) Pre-EF for position with oral Ensure Plus.
 - a) The pre-EF imaging should be started 45-55 minutes post injection of 99mTc Mebrofenin.
 - i) Imaging Parameters: Dynamic acquisition 1 min/frame x 5 frames, 128 x 128, 1.0 zoom, 20% window peaked for 99mTc, with image identifier of **Pre-EF**. (Projection/View not needed as it may be adjusted during this acquisition.) This dynamic image will not be sent to PACS.
 - b) **CHECK POSITIONING WITH NUC MED PHYSICIAN DURING THE previously described DYNAMIC ACQUISITION AND BEFORE ADMINISTERING SINCALIDE.** Stop above acquisition when positioning is approved.
- 5) Post-Ensure Plus Imaging Parameters.
 - a) **ADMINISTER Ensure Plus IF:**
 - i) Most of the activity is in the gallbladder and bowel with relatively little in the liver.
 - ii) Ensure the gallbladder is separated from the duodenum by utilizing the LAO view, if necessary.
 - iii) NM Faculty or Resident could ask for a delay in starting the sincalide infusion. Another pre-infusion imaging set will be required. Exam could also be canceled if the gallbladder does not fill sufficiently.
 - b) Have the patient drink one entire bottle of 8 fl oz of **Ensure Plus® within 2-3 minutes.**
 - c) Dynamic acquisition 1 min/frame x 60 frames, 128 x 128, 1.0 zoom, 20% window peaked for 99mTc, with image identifier of **ANT or LAO EF 1m/f**. Post-Ensure place the patient under the camera as determined above and immediately start the start camera acquisition; this should be 50-60 minutes post 99mTc Mebrofenin injection. The camera is set up to automatically save and transfer images when compete. There is no stopping the acquisition early.

Comments:

A Nuclear Medicine staff or resident physician should be consulted to determine if additional views are indicated.

Division of Nuclear Medicine Procedure / Protocol University Hospital and The American Center

Data Analysis:

Prior to analysis of GBEF perform motion correction.

Analysis

Analyze with the GE Protocol UWH Gallbladder EF. On the GB composite image, the GB ROI is drawn around the gallbladder and the BKGD ROI is drawn to include a segment of the liver and body background. When drawing the ROI's other liver abdominal anatomy is not to be in the region (e.g. bowel or bile ducts). The application uses these ROI's to create a Bkgd corrected GB emptying curve.

The application then selects the frame with the highest counts and uses that to calculate the EF. Verify and adjust the cursor placement as follows; peak activity (green cursor) and nadir/least activity (yellow cursor) are correctly placed on the GB emptying curve then create Dynamic Screen Capture of this GBEF result page, inserting GBEF in front of Dynamic SC (**GBEF Dynamic SC**). Note: The cine **MUST** be running when this dynamic screen cap is saved.

CHECK for any bowel and outside activity interference.

Do a cine review of the dynamic images with the ROI and check for bowel or other activity entering the ROI that is not gallbladder. If there is extra activity, redraw the ROI to eliminate this extra activity. Extra activity causes an error in the GBEF calculation.

PACS Prep

- 1) Reframe the **ANT or LAO EF 1m/f** dynamic image set into a 5 minute/frame image set. Do a Save As, new image series with **ANT or LAO EF 5m/f** as the Series and Image Identifier.
- 2) Screen cap the reframed 5 minute/frame image set, use 4x3 format.
 - a) Annotate -
 - i) Over first image: sincalide dosage. For example, **x.xx mcg sincalide or 8 ounces of Ensure Plus**. Add time post **99mTc-Mebrofenin** if the sincalide started at a different time than the acquisition started.
 - ii) Under first image: **ANT or LAO** (as appropriate) with starting time post mebrofenin injection. For example: **LAO 50 min post 99mTc-Mebrofenin**
 - iii) Add Rt/Lt orientation to first image.
 - iv) Under second image: framing rate: **5 min/frame→**.
 - b) Screen Cap label - add to the front of the screen cap default label: **ANT or LAO EF 5m/f**.

PACS:

- Send all 1-minute dynamic datasets: **As labeled above**
- Send all reframed 5-minute dynamic datasets: **As labeled above**
- Send all Screen Caps: **As labeled above**
- Send the data generated images (automatic GBEF result page): **As labeled above**
- Using paper scanner, scan in **ONLY** the worksheet.

Division of Nuclear Medicine Procedure / Protocol University Hospital and The American Center

Infant: neonatal hepatitis vs biliary atresia

Patient Preps:

- To differentiate between neonatal hepatitis and biliary atresia pre-treatment with Phenobarbital, 5 mg/kg/day given orally in two (2) divided doses for 3-5 days, or ursodeoxycholic salt, 20 mg/kg/day 2-3 days, if needed to increase hepatocyte function, at ordering providers discretion. If patient is already on either of these medications and dosage, no pre-treatment is needed.

Scheduling:

- Allow 90 min of camera time. Delayed images are at 2 hours and 3-4 hours post-injection. Imaging 24 hours post-injection is possible.

Radiopharmaceutical & Dose:

- See Acute Cholecystitis

Imaging Device:

- GE Infinia, Optima or Millennium MPS gamma camera with LEHR collimator.

Imaging Procedure:

- See Acute Cholecystitis

Imaging Procedure:

- See Acute Cholecystitis

PACS:

- See Acute Cholecystitis

Leak

Patient Preps: Imaging Procedure:

- None

Scheduling:

- Allow 90 min of camera time. Delayed images are at 2 hours and 3-4 hours post-injection. Imaging 24 hours post-injection is possible.

Radiopharmaceutical & Dose:

- See Acute Cholecystitis

Imaging Device:

GE Infinia, Optima or Millennium MPS gamma camera with LEHR collimator.

Imaging Procedure:

- 1) Place an IV (per hospital policy).
- 2) Position patient supine under camera.
- 3) Image immediately after injection.
- 4) Imaging parameters: Dynamic acquisition 1 min/frame x 60 frames, 128 x 128, 1.0 zoom, 20% window peaked for 99mTc. Set image identifier to: *Ant 0-60 1m/f*.
 - a) If leak is post-surgical anterior projection is most likely.
 - b) If leak is from trauma anterior and posterior dual head acquisition preferred.

Continues on the next page

Division of Nuclear Medicine Procedure / Protocol University Hospital and The American Center

- 6) If the patient has a drainage bag
 - a) Do your best to get it into the field of view free of body structures.
 - b) If unable to image the drainage bag free of body structures then image bag after the 60-minute dynamic by placing lead under the drainage bag and acquire two static images 128x128, for 5 minutes, 1.0 zoom. Image one is the bag itself. Image 2 using a point source mark the top, bottom and sides of the drainage bag.
 - c) At interpreter request a Right Lateral Decubitus and Right lateral. 128x128, for 5 minutes with 1.0 zoom.
- 7) Delayed static images at 2-4 hours will usually be necessary and 24 hour delayed images may be needed with the same projections as used with initial imaging. 5 minutes per image, 128 x 128, 1.0 zoom, 20% window peaked for 99mTc. Additional projections and/or SPECT/CT could be requested. See Liver/Spleen SPECT protocol for imaging procedure.

Comments:

A Nuclear Medicine staff or resident physician should be consulted to determine if additional views are indicated.

Data Analysis:

- 1) Reframed dynamic 1 minute/frame image set into 5 minute/frame image set;
Image identifier: **Ant 0-60 5m/f.**
- 2) Screen cap reframed 5 minute/frame image set on a 4 x 3 display and annotate -
 - a) Under first image: **ANT 5 min/frame→**
 - b) Screen Cap label - add to the front of the screen cap default label: **Anterior 0-xx min.**
- 3) Screen cap static images on a 4 x 3 display and annotate
 - a) View/projection with time reference post 99mTc-Mebrofenin injection, i.e. **Ant 2-hour delay**
 - b) Add Rt/Lt orientation to first image.
 - c) Screen Cap label - add to the front of the screen cap default label: **Static Delays.**

PACS:

- Send all 1-minute dynamic datasets: **As labeled above**
- Send all 5-minute reframed dynamic datasets: **As labeled above**
- Send all static images: **As labeled above**
- Send all Screen Caps: **As labeled above**
- Using paper scanner, scan in **ONLY** the worksheet.

Division of Nuclear Medicine Procedure / Protocol University Hospital and The American Center

Interpretation (All):

Non-visualization of the gallbladder suggests obstruction of the cystic duct and this is the nuclear medicine physiological requirement of acute calculous or acalculous cholecystitis. In acalculous cholecystitis the cystic duct can be patent resulting in a false negative test.

The gallbladder is normally visualized by 10-15 minutes, somewhat slower in the post-prandial state. Reflux of tracer into the stomach frequently indicates gastric disorder but is common in normal patients.

If there is poor visualization of the intrahepatic biliary ducts or delayed blood clearance, then hepatocyte dysfunction is likely, and the bilirubin should be reviewed. When there is hepatocyte dysfunction, delayed imaging is often needed.

When using morphine, watch for emptying of the duodenum as evidence of spasm of sphincter of Oddi. This is required to raise intra-CBD pressure and therefore fill the gallbladder in chronic cholecystitis and possibly acalculous cholecystitis.

The hepatobiliary scan can actually diagnose obstruction of the CBD prior to US (but this will only occur in first 4 or 5 days). Image for 60 min and then obtain delayed view (4-5 hours). With obstruction, the development of raised intra-CBD pressure occurs, and as this increases and becomes persistent, CBD dilatation occurs. US detection is then very sensitive. With this passage of time there becomes back-pressure on the hepatocyte so that the biliary tract is no longer visualized on our scan, but then hepatocyte dysfunction is documented by delayed plasma clearance of tracer.

In biliary dyskinesia, ensure that patient movement and non-gallbladder tracer do not move out of the ROI used to calculate EF. Tight regions should be created about the gallbladder at the start of the CCK-8 infusion (or Ensure). Without attention to this detail, many false negative and positive scans will occur. The GBEF should be measured with background subtraction and the background should represent contaminating activities (e.g., liver and bowel). The true highest and lowest counts are used if they differ from the automatic calculations. Normal GBEF for our institution is $\geq 38\%$.

In biliary atresia, there is minor urinary excretion (more with Disofenin than Mebrofenin), but no gastrointestinal tract excretion. Severe neonatal hepatitis can emulate biliary atresia but pre-administration of Phenobarbital results in increased hepatobiliary excretion and so separates these two conditions.

In patients with a possible Sphincter of Oddi Dysfunction (SOD), a numerical score should be reported in the interpretation (SOD score > 5 is abnormal).

Division of Nuclear Medicine Procedure / Protocol University Hospital and The American Center

Table: Sostre Criteria for Scoring Scintigrams

All patients with normal sphincter had scores of 0-4. Patients with SOD had values of 5-12

Criteria Score	
1.	1. Peak time
	a. < 10 min 0
	b. 10 min 1
2.	2. Time of biliary visualization
	a. < 15 min 0
	b. ≥ 15 min 1
3.	3. Prominence of biliary tree
	a. Not prominent 0
	b. Prominent major hepatic ducts 1
	c. Prominent small hepatic ducts 2
4.	4. Bowel visualization
	a. < 15 min 0
	b. 15-30 min 1
	c. > 30 min 2
5.	5. CBD emptying
	a. > 50% 0
	b. < 50% 1
	c. No change 2
	d. Shows increasing activity 3
6.	6. CBD-to-liver ratio
	a. CBD (60min) ≤ Liver (60min) 0
	b. Liver (60min) < CBD (60min) < Liver (15min) 1
	c. Liver (60min) < CBD (60min) = Liver (15min) 2
	d. Liver (60min) < Liver (15min) < CBD (60min) 3

Division of Nuclear Medicine Procedure / Protocol University Hospital and The American Center

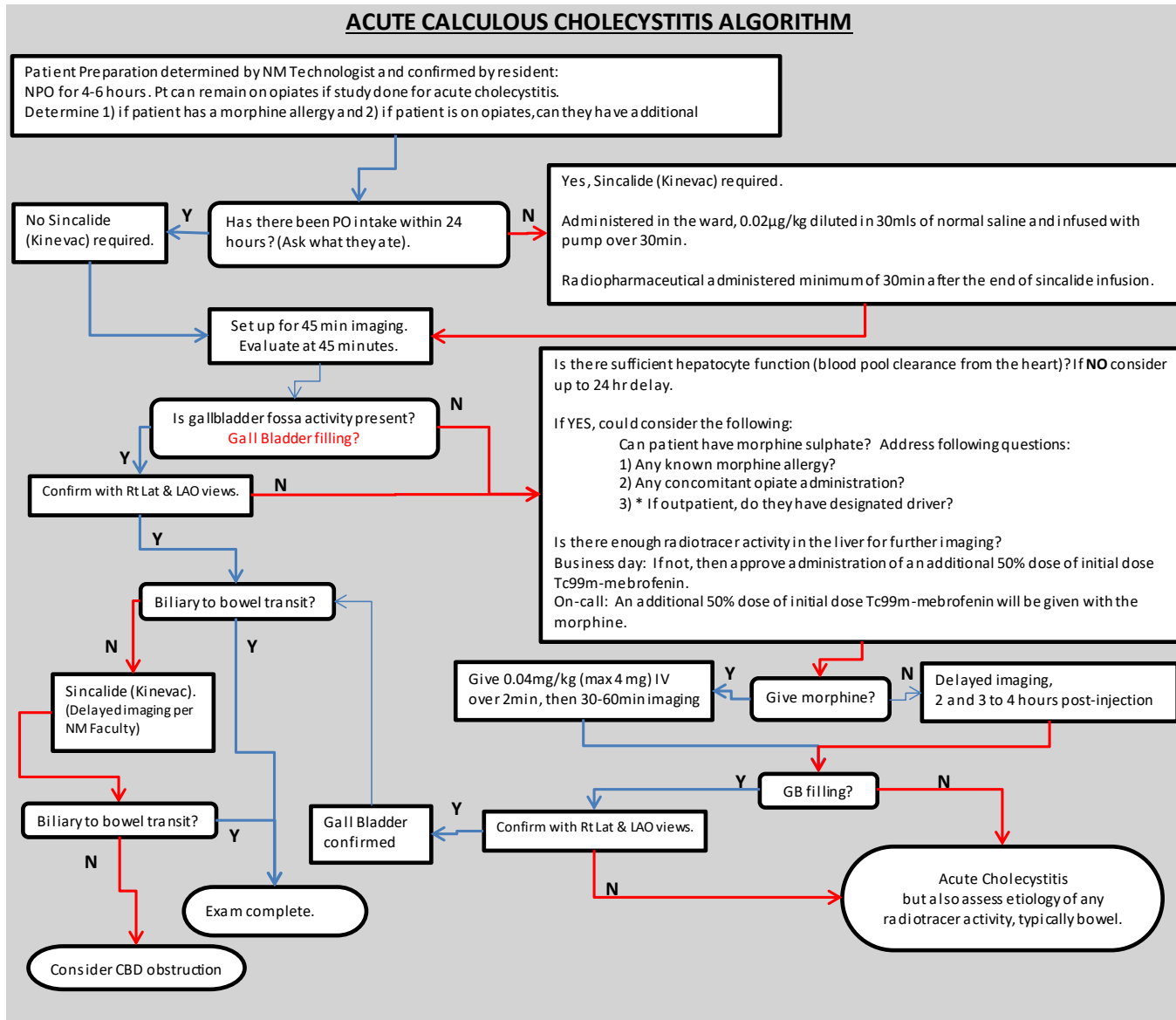
Appendices:

Appendix 1: OPIOID REFERENCE TABLE FOR HEPATOBILIARY SCANNING

Drug	T ½ (hrs) Immediate Release	T ½ (hrs) Extended Release	5 t ½'s (hrs) Immediate Release	5 t ½'s (hrs) Extended Release
Buprenorphine (Belbuca, Butrans) PO, SL, Transdermal Patch, SQ, IV	IV: 2.2 - 3 SL Tab: 37 Transderm: 26		IV: 11 - 15 SL Tab: 185 Transderm: 130	
Codeine PO	2.5 - 3.5		12.5 - 17.5	
Fentanyl (Duragesic) IV, topical, lozenge	IV: 2 - 4 Patch: 20-27		IV: 10 - 20 Patch: 100 - 135	
Hydrocodone (Norco - IR with APAP, Hysingla, Zohydro - ER) PO	3.3 - 4.4	7 - 9	16.5 - 22	35 - 45
Hydromorphone (Dilaudid - IR, Exalgo - ER) IV, PO	2 - 3	11	10 - 15	55
Meperidine (Demerol) IV, PO	2.5 - 4 7 - 11 (liver dx)		12.5 - 20 35 - 55 (liver dx)	
Methadone (Dolophine) PO, IV, IM, SQ	8 - 59		40 - 295	
Morphine (Kadian, MS Contin - ER) IV, PO	2 - 4	12	10 - 20	60
Oliceridine (Olinvyk) IV	1.3 - 3		6.5 - 15	
Oxycodone (IR, Oxycontin - ER) PO	3 - 4	4.5 - 5.5	15 - 20	22.5 - 27.5
Tramadol (ConZip, Ultram) PO	6.3	8 - 10	31.5	40 - 50

Division of Nuclear Medicine Procedure / Protocol University Hospital and The American Center

Appendix 2



Division of Nuclear Medicine Procedure / Protocol University Hospital and The American Center

References:

1. Hepatobiliary Imaging - Sphincter of Oddi Dysfunction, THE JOHNS HOPKINS HOSPITAL DEPARTMENT OF RADIOLOGY AND RADIOLOGICAL SCIENCE POLICY/PROCEDURE MANUAL NUCLEAR MEDICINE, 11-03-2011
2. SNM Practice Guideline for Hepatobiliary Scintigraphy 4.0*, JOURNAL OF NUCLEAR MEDICINE TECHNOLOGY • Vol. 38 • No. 4 • December 2010

Reviewed By: Group review by the Nuclear Medicine Faculty, Residents and Technologists

Scott B. Perlman, MD, MS
Chief, Nuclear Medicine

Derek Fuerbringer, CNMT
Manager, Nuclear Medicine
University Hospital

Sandy Zarada
Manager, Nuclear Medicine
The American Center

Scott Knishka, RPh, BCNP
Radiopharmacist

Tyler Bradshaw, PhD, DABR
Medical Physicist